

Patient Case #1

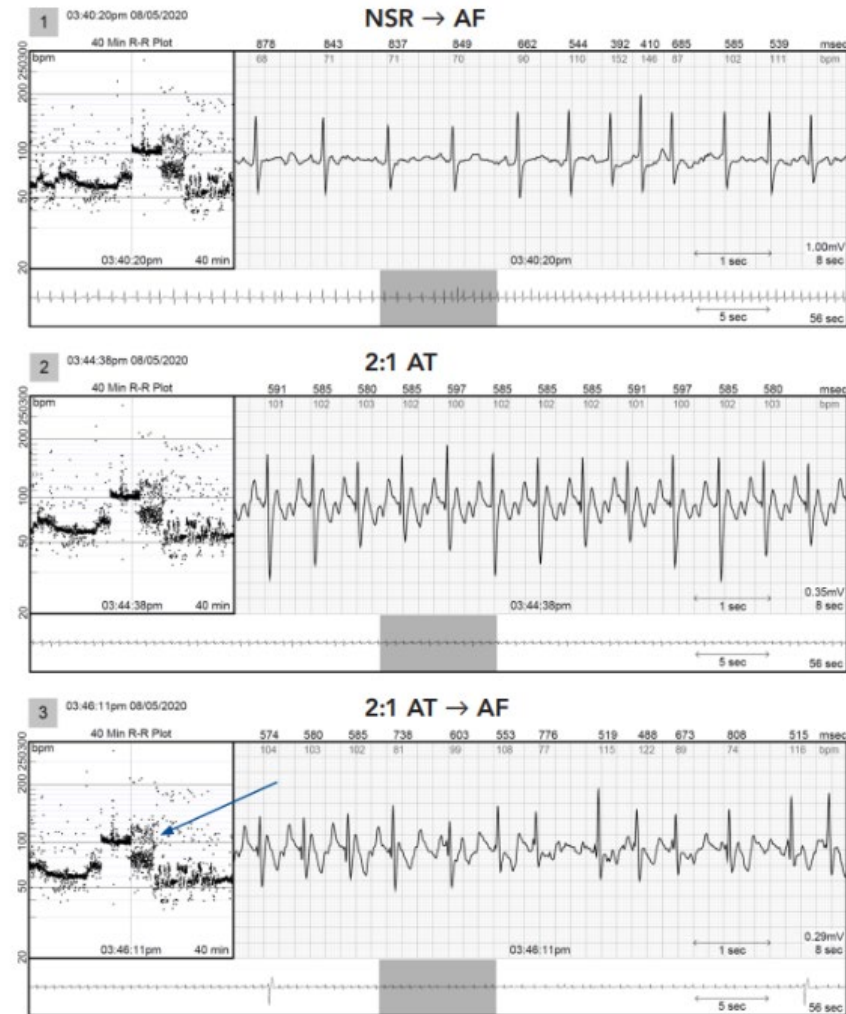
For the following patient with **Paroxysmal Atrial Fibrillation**, does he have other arrhythmias occurring that might be overlooked with less sensitive, **non-P-wave centric cardiac** monitoring options?

How would you treat this patient?

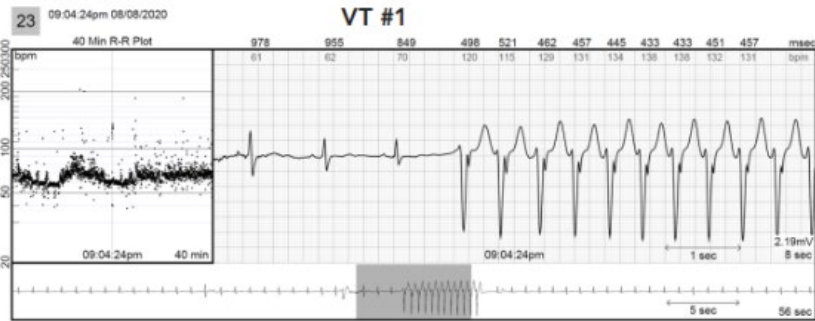73 y/o M with palpitations

In the first three strips to the left, the CAM Patch report indicates this patient went from Normal Sinus Rhythm to Atrial Fibrillation into a 2:1 Atrial Tachycardia, and then back to Atrial Fibrillation within a 40-minute window.

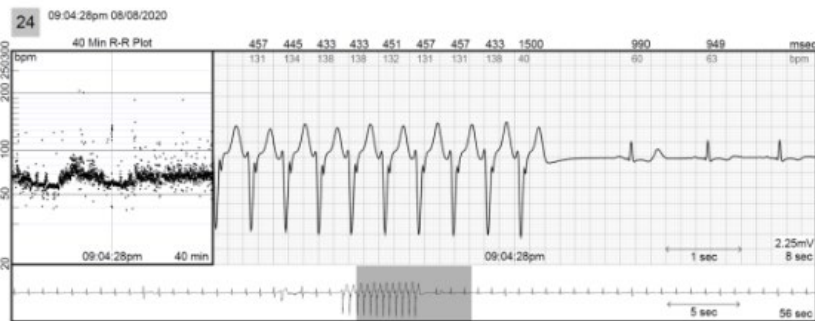
40 min R-R plot showing the transition



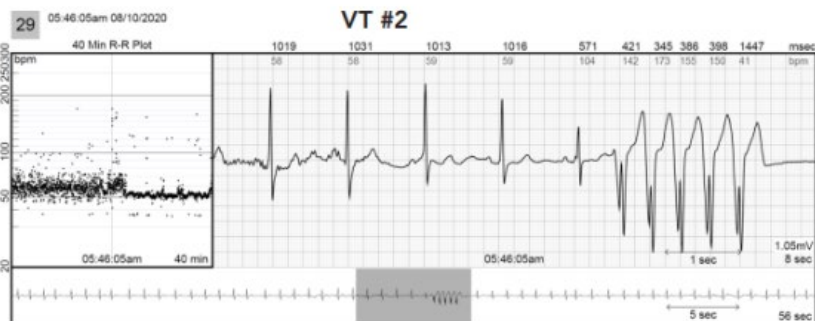Patient Case #1 (continued)



Strips #23, 24, and 29 show two Ventricular Tachycardia morphologies, including onset and offset.



Strips #46–48 show an Atrial Tachycardia transition to AVNRT that ends in a classic P-wave termination.



The R-R plot assists in confirming the diagnosis

